



Dr. med. Duri Gianom

Dig Surg 2003;20:74–78
DOI: 10.1159/000068860

Open and Laparoscopic Treatment of Nonparasitic Splenic Cysts

Duri Gianom^a, Alessandro Wildisen^b, Thomas Hotz^a, Federico Goti^a, Marco Decurtins^a

^aDepartment of Surgery, Kantonsspital Winterthur, and

^bDepartment of Surgery, Kantonsspital Luzern, Switzerland

Key Words

Splenic cyst · Partial splenectomy · Cyst wall unroofing · Laparoscopic surgery

Abstract

Background: Nonparasitic splenic cysts are rare. Therefore, there is no 'evidence-based' information regarding their optimal surgical management. In the last years the laparoscopic approach has gained increasing acceptance in splenic surgery. The aim of this study is to present our experience with the laparoscopic management of splenic cysts. **Methods:** The medical records of 7 patients with splenic cysts were reviewed retrospectively. **Results:** One patient had an open partial splenic resection. Five patients, 3 of them with a posttraumatic and 2 with an epidermoid splenic cyst, underwent laparoscopic unroofing of the cyst. In 4 of these cases the postoperative course was uneventful, whereas in 1 case the patient developed a cyst relapse soon postoperatively. Later on this patient successfully underwent an open partial splenic resection. The 7th patient had an explorative laparoscopy. The cyst was located intrasplenically, entirely covered with unaffected splenic parenchyma, and reached the splenic hilus. Therefore, a conversion to open partial splenectomy was performed. **Conclusion:** Open partial splenectomy and laparoscopic cyst wall unroofing are both effective tools in



the management of splenic nonparasitic cysts. Surgeons must master both techniques as nowadays spleen-preserving techniques should be attempted in every case of splenic nonparasitic cyst.

Copyright © 2003 S. Karger AG, Basel

Introduction

Splenic cysts are rare. Because of the widespread use of abdominal ultrasound, cysts are frequently diagnosed as incidental findings in asymptomatic patients [1]. There is also evidence that, with more patients being managed conservatively for blunt splenic trauma, posttraumatic cyst formation may increase [2]. Therefore surgeons may more often be confronted with the question of optimizing the surgical management of splenic cysts. Due to their rarity, there is no 'evidence-based' solution for the most favorable treatment. On the one hand, the traditionally performed total splenectomy competes with various spleen-preserving procedures, on the other hand the role of laparoscopic treatment of splenic cysts has to be defined.

When minimal invasive surgery was introduced, laparoscopy was not considered to be a feasible method for the treatment of spleen diseases because of the risk of severe hemorrhage. However, due to the progress in surgical techniques, laparoscopic splenic surgery has rapidly developed to a standard procedure [3]. Based on our personal experience in the treatment of 7 giant splenic cysts and along with a review of the current literature, in this article we discuss the value of minimal invasive surgery.

Patients and Methods

The medical records of 7 patients treated between August 1996 and April 2002 for giant splenic cysts were reviewed. There were 3 women and 4 men, their ages were 17, 21, 27, 29, 31, 31 and 36 (mean 27.5) years. One patient had received a body check while playing ice hockey 6 months previously, 1 patient had a car accident 8 years earlier, and a 3rd patient had blunt abdominal trauma without solid organ injury some years ago. Six patients suffered from intermittent left abdominal quadrant pain which led to abdominal sonography in 5 and computer tomography in 1 patient. For 1 asymptomatic patient the diagnosis was made at abdominal sonographic screening for deep femoral vein thrombosis. In all cases the diagnosis was confirmed with an abdominal computed tomography (fig. 1, 2). The cyst diameters were 15, 13, 16, 18, 11, 12 and 10 (mean 13.5) cm.

Blood tests were normal, the serological testing for echinococcus was negative in all cases. One patient had unsuccessful percutaneous aspiration of the cyst 3 years earlier. Surgical therapy was recommended in all cases because of the patients' symptoms and/or cyst size. Since there was a significant portion of nonaffected spleen tissue, a spleen-preserving procedure was chosen in all cases. Three patients had vaccination against pneumococci, and 2 of them also received vaccination against *Haemophilus influenzae*. All patients received perioperative thrombosis prophylaxis with low-molecular weight heparin. A single-shot antibiotic prophylaxis with cefuroxim 1.5 g intravenously was administered in 6 cases. Open resections were performed through a left subcostal incision. After ligation of the small gastric vessels and dissection of retroperitoneal adhesions, the spleen was completely mobilized. After selective ligation of the hilar splenic vessels, resection was performed along the demarcation line

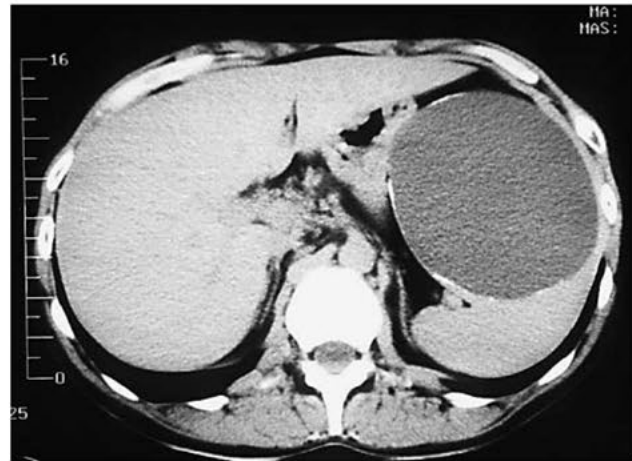


Fig. 1. Abdominal CT scan showing an 11-cm anterior splenic pseudocyst. Successful laparoscopic cyst wall unroofing.

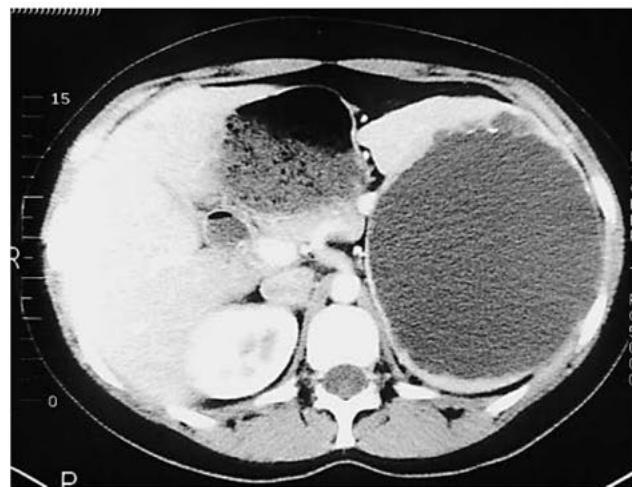


Fig. 2. Abdominal CT scan showing a 16-cm posterior splenic epidermoid cyst. Open partial resection because of suspected echinococcus cyst.

with electrocautery. The resection site was sealed with fibrin glue and oxidized cellulose. In the laparoscopic procedure, the patient was positioned in a 45° right lateral position. The surgeon and the camera assistant stood at the patient's abdominal side. Pneumoperitoneum (14 mm Hg) was applied using an open technique through a 12-mm umbilical port. Under visual control by a 45° laparoscope, a 10-mm trocar was inserted in the left lower abdomen and another 10-mm trocar in the left midaxillary line just below the costal margin. With ultrasonic scissors (Ultracision®, Fa. Ethicon) the splenic flexure of the colon was mobilized. The cyst was then opened and cystic fluid

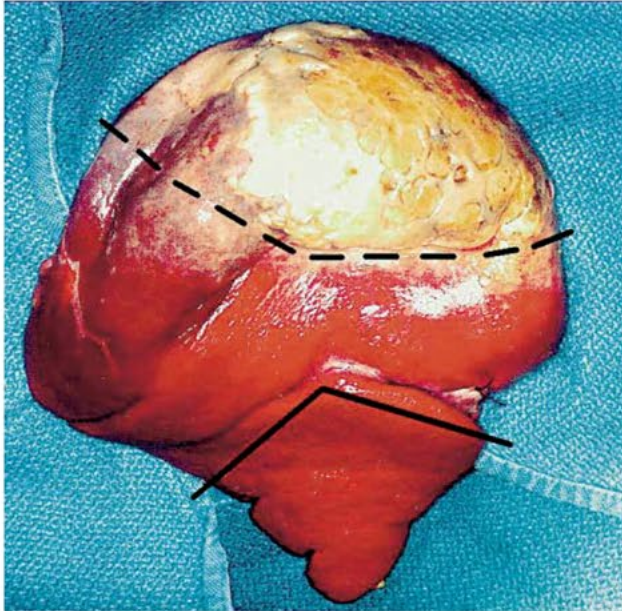


Fig. 3. Intraoperative view of the mobilized spleen (same patient as fig. 2). The continuous line marks the resection site for open partial resection. All the tissue above this line is cyst, covered with healthy splenic tissue. The interrupted line shows the virtual resection line one would choose in laparoscopic unroofing of the cyst wall at the margin of thin avascular cyst wall and wall consisting of splenic parenchyma. This picture shows that in the laparoscopic technique a varying amount of cyst wall must be left in place, which carries the risk of recurrence.

aspirated. In a next step mobilization of the cyst from adhesions to the surrounding tissue followed. After sufficient mobilization, the cyst was widely unroofed until unaffected splenic parenchyma was reached. In 2 cases intraoperative ultrasound was used to mark the margin between the cyst and splenic parenchyma. In 3 cases an omentum plug was placed into the cyst. The excised tissue was then removed with an endoscopic plastic bag and sent for pathological examination. Six patients had Easy-Flow drainage.

Results

One patient, who was suspected of having an echinococcus cyst by CT scan, had an open partial spleen resection. Histology revealed an epidermoid cyst (fig. 2, 3). Six patients were treated laparoscopically. Four patients underwent successful unroofing of the cyst wall. In 3 cases the cysts were located anteriorly and in 1 case posteriorly. In 1 patient, an explorative laparoscopy showed an intrasplenic cyst entirely covered by unaffected splenic parenchyma. A conversion to open partial spleen resection was needed. In the 6th laparoscopically treated patient a posteriorly located cyst was unroofed without any complication. Unfortunately he had cyst relapse soon postoperatively and subsequently underwent an open partial spleen resection. Operation time was 160 and 180 min for the open operations,

170 min for the converted operation and 90, 90, 110, 145 and 180 min for the laparoscopic operations. There was no postoperative morbidity. No perioperative transfusions were administered. Pathological examination showed an epithelial cyst in 4 cases. In 3 cases a fibrotic cyst wall without epithelial lining was found, which is compatible with a posttraumatic pseudocyst. Hospital stay was 7 and 9 days in the open operations, 7 days in the converted operation and 4, 4, 5, 5 and 6 days in the laparoscopic operations. At clinical and radiological (sonography or CT) follow-up 6 months to 4 years post-operatively 6 patients were without symptoms. A small residual fluid collection at the resection site was noticed in the patient whose operation was converted. In 1 patient who was only recently operated no long-term result is available.

Discussion

Splenic cysts are not frequent lesions of the spleen. They can be classified as true or false cysts. True cysts are either parasitic or non-parasitic, whereas false cysts have a posttraumatic origin in most cases. Although parasitic etiology is most common all over the world, in Central Europe and North America cysts are mainly nonparasitic or have a posttraumatic origin [1, 2]. The cysts may be uni- or multilocular and are located subcapsularly, intrasplenicly or at the hilum of the spleen. The majority of splenic cysts cause only vague abdominal symptoms. Therefore, they are often found incidentally during an abdominal ultrasound examination for other reasons. Possible complications are the spontaneous rupture of the cyst with chemical peritonitis or bleeding, abscess formation, hypersplenism and portal hypertension [1, 2].

The indication for a treatment depends mainly on the patient's symptoms and the diameter of the cyst. Cysts larger than 5 cm seem to be prone to complications and therefore treatment is recommended [2]. The goals of treatment are the elimination of the cyst, the avoidance of cyst-related complications and the prevention of recurrence. As shown by 1 of our cases, percutaneous drainage procedures, either alone or in combination with various sclerosing agents, do not result in long-term control of the cystic disease and cannot be recommended [4, 5].

As the indication for an operation is often relative, the choice of surgical technique is of special interest. For a long time, splenectomy was considered to be the treatment of choice for all kinds of splenic lesions. Increasing awareness of potential early and late complications of splenectomy, especially the life-long risk of the development of septic complications, resulted in a more conservative attitude in splenic surgery. At present, splenectomy should be performed only for cysts with unsure dignity or as a salvage procedure, and when spleen-preserving techniques are technically not feasible [6]. If splenectomy is nevertheless planned, the patient should be offered the laparoscopic approach which is nowadays the preferred technique for splenic removal [3].

The spleen has a segmental blood supply and only a small collateral circulation exists between these segments. Especially nonparasitic cysts respect this segmental anatomy. This makes it possible to perform segmental splenic resections without major blood loss. In addition, advances in operative techniques such as splenorrhaphy with resorbable mesh, hemostasis with either fibrin glue, oxidized cellulose or argon beam coagulation and stapler techniques have made spleen-preserving procedures safe and feasible. Based on these anatomic and technical findings, many authors, especially in the

**Table 1.** Summary of reported cases of laparoscopically treated splenic cysts

Author	n	Cyst type	Location/size	Outcome
Sardi et al. [4], 1998	1	epidermoid	anterior/20 cm	residual cyst
Salky et al. [15], 1985	1	epidermoid	upper pole, anterior/?	good
Cala et al. [16], 1996	1	pseudocyst	upper pole/6 cm	good
Seshadri et al. [17], 1998	1	epidermoid	upper pole, anterior/15 cm	residual cyst
Targarona et al. [19], 1995	1	pseudocyst	lower pole, anterior/10 cm	good
Reck et al. [20], 1992	3	epidermoid	anterior/11 cm	good
		pseudocyst	upper pole/20 cm	residual cyst
		pseudocyst	upper pole, posterior/8 cm	good
Posta et al. [21], 1994	1	epidermoid	upper pole, anterior/6 cm	residual cyst
Heintz et al. [22], 1995	2	pseudocyst	?/10 cm	good
		pseudocyst	anterior/7 cm	residual cyst
Heidenreich et al. [23], 1996	1	epidermoid	lower pole/8 cm	good
Feliciotti et al. [24], 1996	2	pseudocyst	posterior/11 cm	good
		pseudocyst	lower pole/8 cm	good
Calligaris et al. [25], 1996	1	pseudocyst	lower pole, anterior/9 cm	residual cyst
Bove et al. [26], 1996	2	pseudocyst	anterior/?	good
Sellers et al. [27], 1997	1	epidermoid	upper pole, posterior/12 cm	good
Schwetling et al. [28], 1997	1	epidermoid	?	good
Trias et al. [29], 1998	2	pseudocyst	?	good
Sobrado et al. [30], 1998	1	epidermoid	upper pole/7 cm	good
van der Zee et al. [31], 1999	1	pseudocyst	anterior/17 cm	good
Fahel et al. [32], 2000	1	pseudocyst	lower pole/?	good
Jamshidi et al. [33], 2001	2	pseudocyst	lower pole, anterior/8 cm	good
		pseudocyst	lower pole, posterior/10 cm	good
Marusch et al. [34], 2001	1	epidermoid	upper pole, anterior/7 cm	good

pediatric literature, have reported excellent results with partial splenectomy of splenic nonparasitic cysts [7–9]. Partial splenectomy is a demanding procedure which requires high technical skill, but offers a definitive solution to the problem. So far, partial splenic resections have mainly been performed through laparotomy. In the recent literature, there are only 4 reports with 5 cases of successful laparoscopic partial splenic resections [10–13].

At least 25% of the spleen parenchyma should be preserved for adequate postoperative spleen function [14]. In very large cysts with a small amount of normal spleen parenchyma, the technical fulfillment of this assumption may be very difficult. Nevertheless, in this situation, simple unroofing of the cyst wall offers a valid alternative to partial spleen resection or splenectomy. However, if performed in an open technique, this minor procedure requires wide mobilization of the spleen by way of a large laparotomy. Laparoscopy offers the advantages of minimal access surgery, however granting a definitive solution.

Laparoscopic unroofing of a splenic cyst was introduced by Salky et al. [15] in 1985. They opened a 3-cm window in a posttraumatic cyst. A CT scan showed no residual lesion 8 months later [15]. Since then, including our 4 cases, 32 case reports have demonstrated the feasibility of laparoscopic cyst wall unroofing (table 1). Of 3 cases reported by Cala et al. [16], 2 cases were converted to open resection because of adhesions surrounding the spleen in 1 case and the intrasplenic location of the cyst in the other case [16]. No conversions due to bleeding complications are reported. The postoperative course

was uneventful in all reported cases. Most authors used electrocautery or ultrasonic scissors for cyst wall resection. In 1 case an endoscopic stapler was used to facilitate dissection through the vascularized cyst wall [17].

Cyst recurrence seems to be the major problem of the laparoscopic technique [18]. Seven (22%) patients of 32 developed cyst recurrence. In most cases residual cysts were small and asymptomatic and needed no further treatment. Of the cases mentioned with residual cyst, only 1 patient was reoperated, again by laparoscopic unroofing of the cyst wall [4]. In our case, in which the cyst remained large, further treatment was indicated because the goal of previous treatment, i.e. the avoidance of possible complications, had not been achieved. To minimize the risk of recurrence, the largest possible amount of the cyst wall should be resected [19]. In most cases, resection of the cyst wall is terminated when the unaffected splenic parenchyma is reached. Otherwise, laparoscopically untreatable bleeding can occur. Therefore, a varying amount of the cyst wall must be left in place. Because of the softness of the spleen, this may result in cyst wall collapse which makes open drainage into the peritoneal cavity impossible (fig. 2, 3). To prevent the collapse, some authors recommend suturing or stapling an omentum plug into the remaining cavity, as we did in 3 cases [17, 20].

To summarize, regarding the choice of optimal surgical technique, no final judgement can be made. In our experience, open partial splenic resection and laparoscopic cyst wall unroofing are both effective tools in the management of nonparasitic splenic cysts. In the



case of a superficial cyst at the anterior surface of the spleen (fig. 1), laparoscopic unroofing of the cyst wall is an easy procedure which offers the patient all the benefits of minimal access surgery. Cysts in the posterior surface of the spleen are found to be more difficult for a laparoscopic treatment since the spleen has to be widely mobilized. In the case of a centrally located splenic cyst, a laparoscopic procedure should not be attempted [16]. These difficult cases are probably best treated by open partial splenic resection. Therefore, surgeons should master open and laparoscopic spleen-preserving techniques with the aim of avoiding splenectomy whenever possible.

References

- 1 Klee FE, Osswald BR, Wysocki S: Splenic cyst – A classical 'incidental finding' (in German). *Zentralbl Chir* 1996;121:805–816.
- 2 Pachter HL, Hofstetter SR, Elkowitz A, Harris L, Liang HG: Traumatic cysts of the spleen – The role of cystectomy and splenic preservation: Experience with seven consecutive patients. *J Trauma* 1993;35:430–436.
- 3 Rosin D, Brasco O, Rosenthal RJ: Laparoscopic splenectomy: New techniques and indications (in German). *Chirurg* 2001;72:368–377.
- 4 Sardi A, Ojeda HF, King D: Laparoscopic resection of a benign true cyst of the spleen with the harmonic scalpel producing high levels of CA 19-9 and carcinoembryonic antigen. *Am Surg* 1998;64:1149–1154.
- 5 Moir C, Guttman F, Jequier S, Sonnino R, Youssef S: Splenic cysts: Aspiration, sclerosis, or resection. *J Pediatr Surg* 1989;24:646–648.
- 6 Wolters U, Keller HW, Lorenz R, Pichlmaier H: Splenic cysts: Indications for surgery and surgical procedures (in German). *Langenbecks Arch Chir* 1990;375:231–234.
- 7 Wirth H, Brands W, Schaupp W: Milzerhaltende Therapie bei Milzzysten. *Chir Gastroenterol* 1993;9(suppl 2):39–40.
- 8 Brown MF, Ross AJ, Bishop HC, Schnauffer L, Ziegler MM, Holcomb GW: Partial splenectomy: The preferred alternative for the treatment of splenic cysts. *J Pediatr Surg* 1989;24:694–696.
- 9 Wit J, Flegel A, Golla S, Mau H: Surgical therapy of monstrous splenic cysts in childhood. *Chir Gastroenterol* 2001;17:6–10.
- 10 Poulin EC, Thibault C, DesCoteaux JG, Cote G: Partial laparoscopic splenectomy for trauma: Technique and case report. *Surg Laparosc Endosc* 1995;5:306–310.
- 11 Soares RL Jr, Balder DA, Migliori SJ, Amaral JF: Laparoscopic complete excision of a splenic epidermoid cyst. *J Laparoendosc Adv Surg Tech A* 1998;8:237–240.
- 12 Seshadri PA, Poulin EC, Mamazza J, Schlachta CM: Technique for laparoscopic partial splenectomy. *Surg Laparosc Endosc Percutan Tech* 2000;10:106–109.
- 13 Kaiwa Y, Kurokawa Y, Namiki K, Matsumoto H, Satomi S: Laparoscopic partial splenectomies for true splenic cysts. A report of two cases. *Surg Endosc* 2000;14:865.
- 14 Eber SW, Bolkenius M, Heidemann P, Langendörfer CM, Mex G, Reinhardt D, Riekhof J, Stöhr G: Subtotal splenectomy in hereditary spherocytosis during childhood. *Chir Gastroenterol* 2001;17:12–17.
- 15 Salky B, Zimmermann M, Bauer J, Gelernt I, Kreel I: Splenic cyst – Definitive treatment by laparoscopy. *Gastrointest Endosc* 1985;31:213–215.
- 16 Cala Z, Cvitanovic B, Perko Z, Velnic D, Rasic Z: Laparoscopic treatment of nonparasitic cysts of spleen and liver. *J Laparoendosc Surg* 1996;6:387–391.
- 17 Seshadri PA, Poenaru D, Park A: Laparoscopic splenic cystectomy: A case report. *J Pediatr Surg* 1998;33:1439–1440.
- 18 Litwin DEM, Kelly JJ, Callery MP: Laparoscopic surgery of the spleen, adrenal and pancreas; in Brooks DC (ed): *Current Review of Minimally Invasive Surgery*. Berlin, Springer, 1998, pp 87–98.
- 19 Targarona EM, Martinez J, Ramos C, Becerra JA, Trias M: Conservative laparoscopic treatment of a posttraumatic splenic cyst. *Surg Endosc* 1995;9:71–72.
- 20 Reck T, Köckerling F, Gastinger I, Schneider B, Schneider I, Gall FP: Die laparoskopische Resektion grosser Milzzysten. *Minimal Invas Chir* 1992;1:106–112.
- 21 Posta CG: Laparoscopic management of a splenic cyst. *J Laparoendosc Surg* 1994;4:347–354.
- 22 Heintz A, Junginger T: Laparoscopic surgery of cysts of the liver, spleen and mesentery. *Dt Med Wochenschr* 1995;120:201–204.
- 23 Heidenreich A, Canero A, di Pasquo A: Laparoscopic approach for treatment of a primary splenic cyst. *Surg Laparosc Endosc* 1996;6:243–246.
- 24 Feliciotti F, Sottili M, Guerrieri M, Paganini AM, Lezoche E: Conservative ultrasound-guided laparoscopic treatment of posttraumatic splenic cysts: Report of two cases. *Surg Laparosc Endosc* 1996;6:322–325.
- 25 Calligaris L, Bortol M: Laparoscopic treatment of a nonparasitic splenic cyst: Case report. *J Laparoendosc Surg* 1996;6:431–434.
- 26 Bové T, Delvaux G, Van Eijkelenburg P, De Backer A, Willems G: Laparoscopic-assisted surgery of the spleen: Clinical experience in expanding indications. *J Laparoendosc Surg* 1996;6:213–217.
- 27 Sellers GJ, Starker PM: Laparoscopic treatment of a benign splenic cyst. *Surg Endosc* 1997;11:766–768.
- 28 Schwetling R, Anders S, Bärlechner E: Laparoscopic splenic surgery – Report about 17 personal cases (in German). *Zentralbl Chir* 1997;122:291–294.
- 29 Trias M, Targarona EM, Espert JJ, Balague C: Laparoscopic surgery for splenic disorders. *Surg Endosc* 1998;12:66–72.
- 30 Sobrado CW, Mackdisse F, da Rocha JRM, Mester M, Nahas SC, Habr-Gama A: True splenic cyst treated with videolaparoscopy. Case report and review of the literature (in Portuguese). *Rev Hosp Clin Fac Med Sao Paulo* 1998;53:260–262.
- 31 van der Zee DC, Kramer WLM, Ure BM, Mokhaberi B, Bax NMA: Laparoscopic management of a large posttraumatic splenic cyst in a child. *Surg Endosc* 1999;13:1241–1242.
- 32 Fabel E, Amaral PCG, Filho AMA, Ettinger JETM, et al: Videolaparoscopic approach of the splenic cyst: A case report. *JLS* 2000;4:23–26.
- 33 Jamshidi M, Chang E, Smaroff G, Mehta J, Ghani A: Laparoscopic fenestration and modified marsupialization of posttraumatic splenic cysts using a harmonic scalpel. *Surg Endosc* 2001;15:758.
- 34 Marusch F, Koch A, Zippel R, Muth CP, Gastinger I: Laparoscopy of a traumatic rupture of a dysontogenetic splenic cyst. A case report. *Surg Endosc* 2001;15:759.

Dr. D. Gianom, Kreisspital Männedorf, Asylstrasse 10
CH-8708 Männedorf (Switzerland)
Tel. +41 1 922 25 03, Fax +41 1 922 25 05
E-Mail d.gianom@spitalmaennedorf.ch